
Successful Spine-Shortening Osteotomy for Recurrent Tethered Cord Syndrome: A Case Report

Pooria Hosseini^{1*}, Gregory Mundis¹ and Rui Antão²

¹Sports and Medicine Traumatology, Department of Orthopedic Spine Surgery, Coimbra, Portugal

²Department of Medicine and Orthopaedics, British Hospital, Lisbon, Portugal

***Corresponding author:** Pooria Hosseini, Sports and Medicine Traumatology, Department of Orthopedic Spine Surgery, Coimbra, Portugal. E-mail: phosseini@spinefoundation.ac.pt

Received: September 30, 2022; **Accepted:** October 18, 2022; **Published:** November 10, 2022

Abstract

The authors report a rare case of recurrent tethered cord syndrome in the context of Ehlers Danlos Syndrome and mosaic trisomy chromosome 20 that was successfully treated by shortening vertebral column with a partial corpectomy. The patient was a 20-year-old female diagnosed with Ehlers Danlos type 3 and mosaic trisomy 20. Her lower extremities sensation and strength gradually deteriorated, and a clinical and radiographic diagnosis of tethered cord syndrome was made. She underwent three detethering surgeries, which all were complicated with retethering and arachnoid cyst formation. The massive amount of scar formation found on the third attempt at detethering surgery forced the surgeon to leave the spinal cord tethered and plan for spinal-shortening osteotomy. At 11 vertebral column resection shortened the spine by 20mm and allowed gradual and significant recovery of lower limb neurological deficits. Authors reported this rare case to (a) propose the consideration of the spine-shortening osteotomy as the primary surgery in a tethered cord syndrome patient with a higher possibility of scar formation like Ehlers Danlos Syndrome (b) and to report a rare case of tethered cord syndrome in the context of Ehlers Danlos Syndrome with mosaic trisomy 20 and (c) raise the awareness of the possibility of unreported genetic association of Ehlers Danlos Syndrome with mosaic trisomy 20.

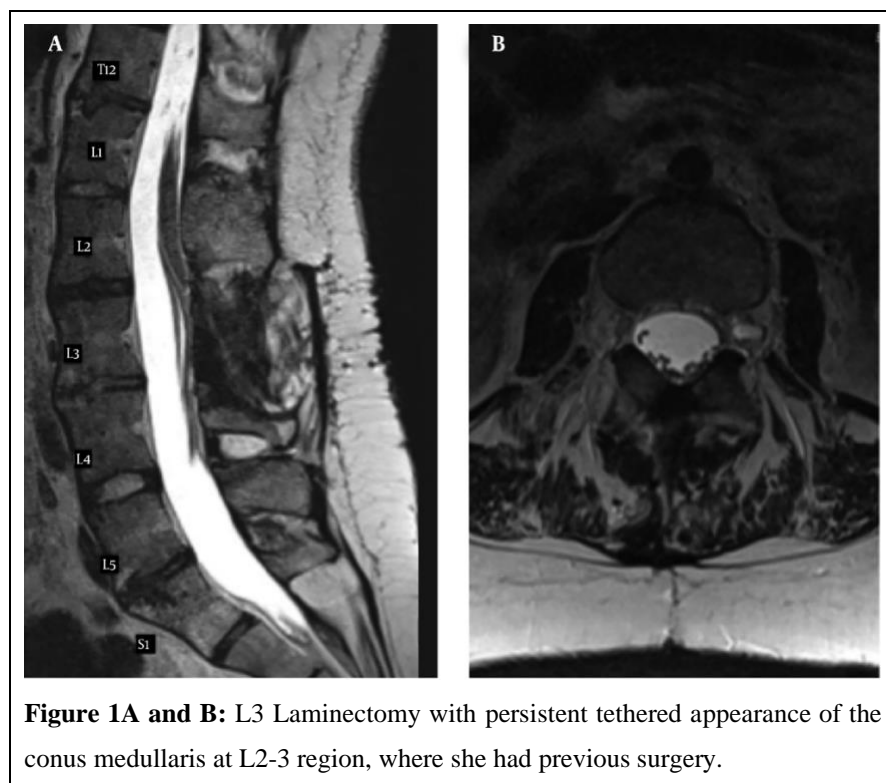
Keywords: Recurrent tethered cord syndrome; Spine-shortening osteotomy; Ehlers danlos syndrome; Mosaic trisomy 20

Introduction

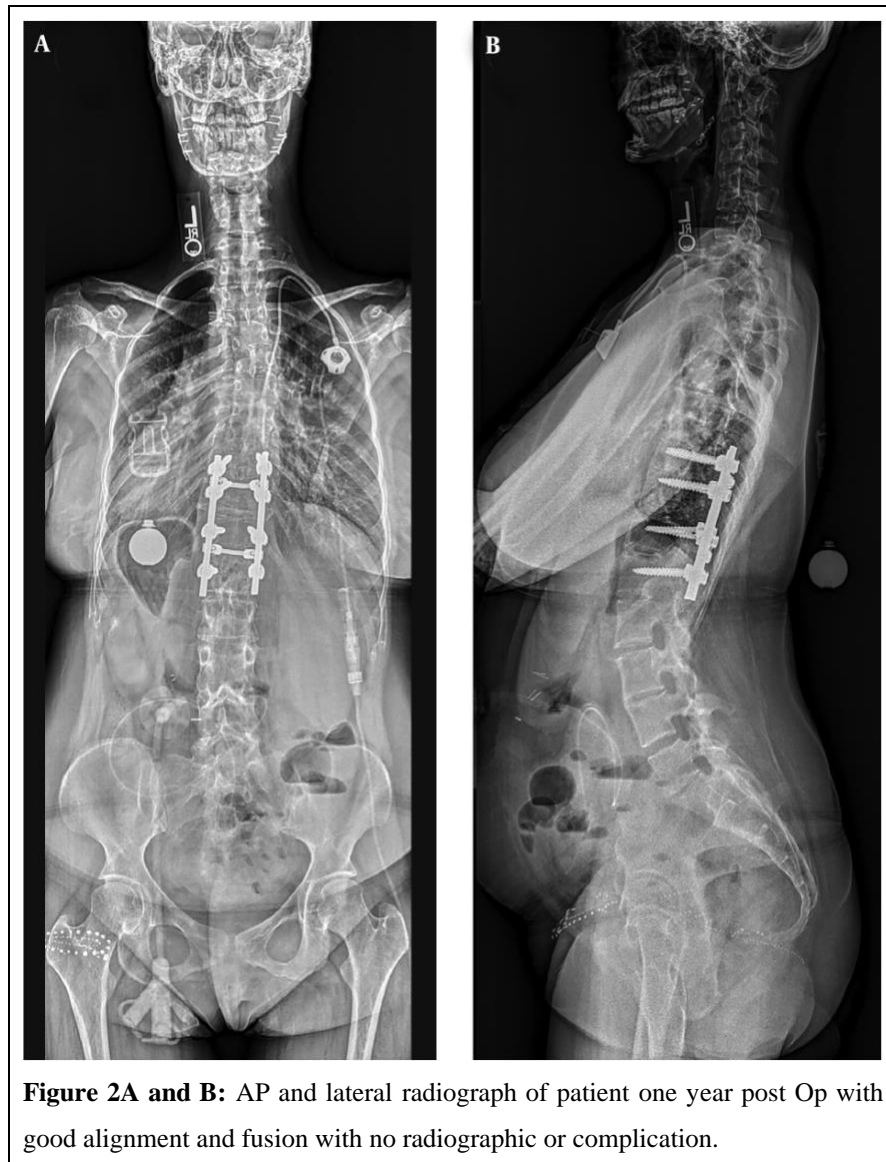Tethered cord syndrome (TCS) is a clinical condition with multiple etiologies. It is characterized by traction on nerve roots and the spinal cord, which can cause pain and neurological symptoms. TCS may also cause limb and spinal deformities [1,2]. Surgical management of TCS is highly recommended especially in young and symptomatic patients. Traditionally, detethering is attempted first and spine-shortening osteotomy is reserved for recurrent TCS scenarios [3]. Ehlers Danlos syndrome (EDS) is an autosomal dominant connective-tissue disorder which is classified into several primary types [3].

Case Report

A 20-year-old female with kyphoscoliosis was diagnosed with TCS. Detethering surgery was performed with uneventful postsurgical recovery. About one year later the neurological signs and symptoms including decreased general lower extremities' strength and sensation recurred. MRI confirmed the TCS recurrence and arachnoid cyst formation (Figure 1). Laminectomy resection of intradural lumbar arachnoid cyst and detethering of tethered cord was performed under neurophysiologic monitoring. However, postoperatively the operation became complicated with cerebrospinal fluid (CSF) leak that caused great difficulty with headaches and getting out of bed and required multiple blood patches. Initially patient had return of her strength and sensation. However, over two months, lower extremity strength gradually deteriorated again and sensation severely decreased. Recurrent arachnoid cyanate their cord syndrome was diagnosed based on repeat MRI. Urgent arachnoid cyst resection and untethering was attempted. The arachnoid cyst was surgically decompressed. However, the attending surgeon was not able to untether the cord the third time due to extremely heavy scar formation at the site of tethering and a spine-shortening osteotomy was planned to deal with recurrent TCS later. One-week later patient underwent a partial vertebral column resection (VCR) of 20mm at T11 performed by lateral extra cavitory approach and partial corpectomy of T11 associated with posterior segmental instrumentation from T9-L1.



Patient had immediate return of some lower extremity neurologic function and continued to see gradual improvement over the following year post-operatively. She improved from being 1/5 strength pre-operatively and now can ambulate independently. She is still experiencing lack of proprioception, pain and temperature, and light touch in bilateral lower extremities. Her lower limb motor functions are 4/5 bilaterally in iliopsoas, quadriceps, tibialis anterior, extensor hallucis longus, and gastroc-soleus muscle groups. Post-operative radiographs of the patient with good alignment and fusion have been demonstrated in (Figure 2).



Discussion

Among different presentations of EDS, increased tendency for scar formation has been reported, which is secondary to abnormal collagen formation [4]. It has also been reported that wounds of patient with EDS are hard to heal [5]. However, when they heal, they form scars that widen with time and resemble “cigarette paper” [6]. These “cigarette paper” scars even can occur at the site of very minor surgical procedures [7].

The association between TCS and EDS has been previously discussed [8]. To our best knowledge, there is no published report of TCS in the context of Ehlers Danlos syndrome (EDS). However, only one meeting abstract exists regarding the concurrence of TCS with vascular form of EDS in two patients [9]. Here, we presented a rare TCS case in the context of EDS, which might further potentiate a relation between these entities. Moreover, the EDS of our case was accompanied with mosaic trisomy 20, a finding that has not been noticed in the earlier investigations.

Surgical management of recurrent TCS is also a challenging subject. Detethering is a well-established surgical treatment for TCS [10]. However, detethering often causes retethering and recurrence of symptoms due to scar formation. Retethering has been reported in 5% to 50% of patients [11]. Surgery for recurrent TCS often gets complicated due to neurological and surgical site complications [11]. In addition, multiple repeated surgeries increase the risks of iatrogenic injuries, which consequently diminish benefits of the surgical treatment [12].

Considering the short shortfalls of these traditional detethering surgeries [13]. Introduced a spine-shortening procedure that relieved tension on the neural elements without violating the dura. Spine-shortening osteotomies at thoracolumbar region is theorized to indirectly relieving tension on the tethered neural elements at lower levels [14]. Accordingly, the patient in the current report was treated with spine shortening osteotomy of 20mm after multiple failed detethering attempts. To prevent kinking of the spinal cord and consequent neurological deterioration, osteotomies more than two-thirds of vertebral segments are not recommended [15] and a 20mm shortening is considered safe and efficient for tension reduction [16]. However, the exact amount of shortening osteotomy to achieve the best neurological outcomes is still unknown [17].

Recommended shortening osteotomies in primary and recurrent TCS cases without local mass effects or symptoms that can be tackled with detethering surgeries. In a cadaveric study [18], recommended spine-shortening osteotomies as an alternative to detethering surgeries when the risk of complications is high due to the presence of massive scar at tethered cord region. In their study, a 20-25mm osteotomy at T11-T12 reduced tension in the lumbar and sacral nerve roots and the terminal filum from 4.6 g to less than 0.6 g. This amount of achieved tension reduction by osteotomy was equivalent to a simulated traditional detethering operation. By highlighting the recurrence of neurological symptoms in half of Kokuban's cases, Traynel is debated that spine-shortening osteotomy should be reserved for recurrent TCS cases until its role as a primary procedure for TCS is further defined. However, Kokubun proposed that delaying osteotomy treatment by trial-and-error detethering surgery will impose more scar formation and less oxygen supply to the spine, which might be responsible for less favorable long-term neurological recovery after osteotomy as a secondary option. Traynel is did agree that there are some certain cases of TCS that might benefit from primary osteotomy [16,17].

Considering the current and previous case reports and cadaveric studies, the authors would like to propose at least the consideration of primary spine-shortening osteotomy in a TCS patient with disorders that increase the risk of scar formation like EDS. In addition, we felt that it was important to report the recurrence of tethering in the context of EDS to raise the awareness of the possibility of increased risk of retethering specifically when the patient suffers from a connective tissue disorder like EDS. On the other hand, authors admit that the spineshortening osteotomy is a major surgery with considerable complications [20]. Hence, advantages and disadvantages of offering spine-shortening osteotomy as a primary. Based on the findings of the current case, authors theorized that there might be a genetic correlation between mosaic trisomy 20 and EDS. Authors admit that this is just a single case report and the occurrence of trisomy 20 and EDS might have happened just as a coincidence. Future reports of similar findings if observed would be valuable and help in better understanding the rate of retethering in EDS, the best initial surgical option in EDS with TCS, and the possibility of further genetic correlations between EDS and unreported genes.

REFERENCES

1. Agarwalla PK, Dunn IF, Scott RM, et al. Tethered Cord Syndrome. *Neurosurg Clin N Am.* 2007; 18: 531-547.
2. Barutcuoglu M, Selcuki M, Umur AS, et al. Scoliosis May be the First Symptom of the Tethered Spinal Cord. *Indian J Orthop.* 2016; 50: 80-86.
3. Leganger J, Soborg ML, Farholt S, et al. Ehlers-Danlos Syndrome. *Ugeskr Laeger.* 2016; 178.
4. Shirley ED, Demaio M, Bodurtha J. Ehlers-Danlos Syndrome in Orthopaedics: Etiology, Diagnosis, and Treatment Implications. *Sports Health.* 2012; 4: 394-403.
5. Ryan N, Walkden G, Akbar S, et al. Some Wounds are Hard to Heal: An Interesting Presentation of Ehlers-Danlos Syndrome. *J Wound Care.* 2012; 21.
6. Halim AS, Emami A, Salahshourifar I, et al. Keloid Scarring: Understanding the Genetic Basis, Advances, and Prospects. *Arch Plast Surg.* 2012; 39: 184-189.
7. Stanford DG, Georgouras KE. Ehlers-Danlos Syndrome Type II: Importance of Recognition. *Australas J Dermatol.* 1995; 36: 153-155.
8. Henderson FC, Austin C, Benzel E, et al. Neurological and Spinal Manifestations of the Ehlers–Danlos Syndromes. *Wiley Online Library.* 2017.
9. Bangura S, Griswold BF, Sloper L, et al. Tethered Spinal Cord in Patients with Vascular Ehlers-Danlos Syndrome. *The American Society of Human Genetics.* 2008.
10. Lee GY, Paradiso G, Tator CH, et al. Surgical Management of Tethered Cord Syndrome in Adults: Indications, Techniques, and Long-term Outcomes in 60 Patients. *J Neurosurg Spine.* 2006; 4: 123-131.
11. Hsieh PC, Stapleton CJ, Moldavskiy P, et al. Posterior Vertebral Column Subtraction Osteotomy for the Treatment of Tethered Cord Syndrome: Review of the Literature and Clinical Outcomes of all Cases Reported to Date. *Neurosurg Focus.* 2010; 29: E6.
12. Al-Holou WN, Muraszko KM, Garton HJ, et al. The Outcome of Tethered Cord Release in Secondary and Multiple Repeat Tethered Cord Syndrome. *J Neurosurg Pediatr.* 2009; 4: 28-36.
13. Kokubun S. Shortening Spinal Osteotomy for Tethered Cord Syndrome in Adults. *Spine Spinal Cord.* 1995; 8: 5.
14. Kanno H, Aizawa T, Ozawa H, et al. Spineshortening Vertebral Osteotomy in a Patient with Tethered Cord Syndrome and a Vertebral Fracture. *Case Report. J Neurosurg Spine.* 2008; 9: 62-66.
15. Kawahara N, Tomita K, Kobayashi T, et al. Influence of Acute Shortening on the Spinal Cord: An Experimental Study. *Spine (Phila Pa 1976).* 2005; 30: 613-620.
16. Kokubun S, Ozawa H, Aizawa T, et al. Spine-shortening Osteotomy for Patients with Tethered Cord Syndrome Caused by Lipomyelomeningocele. *J Neurosurg Spine.* 2011; 15: 21-27.
17. Traynelis VC. Spine Shortening of Tethered Cord. *J Neurosurg Spine.* 2011; 15: 19-20.
18. Grande AW, Maher PC, Morgan CJ, et al. Vertebral Column Subtraction Osteotomy for Recurrent Tethered Cord Syndrome in Adults: A Cadaveric Study. *J Neurosurg Spine.* 2006; 4: 478-84.
19. Ikenaga M, Shikata J, Takemoto M, et al. Clinical Outcomes and Complications After Pedicle Subtraction Osteotomy for Correction of Thoracolumbar Kyphosis. *J Neurosurg Spine.* 2007; 6: 330-336.